

Prepuce-sparing plasty and simple running suture for phimosis

C. MONARCA, M.I. RIZZO, L. QUADRINI, G. SANESE, G. PREZZEMOLI, N. SCUDERI

SUMMARY: Prepuce-sparing plasty and simple running suture for phimosis.

C. MONARCA, M.I. RIZZO, L. QUADRINI, G. SANESE, G. PREZZEMOLI, N. SCUDERI

Aim. Circumcision is the most common procedure for phimosis. In recent years, the value of foreskin properties as well as aesthetic reasons determined to other operations preserving the foreskin. We report 5-years experience with a technique that preserve the physical foreskin appearance intact.

Patients and methods. Fifty-two patients, eligible to undergo phimosis surgery, underwent prepuce-sparing plasty and simple running suture. Evaluation of results was made with photos comparative and verified by using presence/absence of recurrence, scarring evaluation, and VAS for patient satisfaction.

Results. Forty-eight patients reported no complications. There were no cases of bleeding, infection, pathological scarring, phimosis recurrence. The scar showed a good pliability and a thin thickness. Patient satisfaction was high.

Conclusions. The association of prepuce-sparing plasty and simple running suture highlighted an effective and easy method for the correction of acquired phimosis in adult patients, with excellent functional and cosmetic results.

RIASSUNTO: Prepuzioplastica con risparmio cutaneo e sutura in soprappiglio semplice per il trattamento della fimosi.

C. MONARCA, M.I. RIZZO, L. QUADRINI, G. SANESE, G. PREZZEMOLI, N. SCUDERI

Obiettivo. La procedura più comune per il trattamento della fimosi è da sempre la circoncisione, anche se negli ultimi anni si stanno diffondendo tecniche chirurgiche che cercano di preservare il prepuzio per ragioni funzionali ed estetiche. Riportiamo 5 anni di esperienza con una tecnica di prepuzioplastica che mantiene intatto l'aspetto del prepuzio.

Pazienti e metodi. 52 pazienti affetti da fimosi sono stati sottoposti a prepuzioplastica con risparmio cutaneo e soprappiglio semplice. La valutazione dei risultati è stata fatta mediante foto comparative e verificando eventuale recidiva, cicatrizzazione e soddisfazione del paziente.

Risultati. 48 pazienti non riportavano complicazioni. Nessun caso di sanguinamento, infezione, cicatrice patologica. La cicatrice risultava elastica e sottile. Il grado di soddisfazione del paziente era alto.

Conclusioni. L'associazione di prepuzioplastica con risparmio cutaneo e soprappiglio semplice rappresenta un metodo semplice ed efficace per correggere la fimosi in pazienti adulti con eccellenti risultati morfofunzionali.

KEY WORDS: Phimosis - Circumcision - Prepuce-sparing plasty - Simple running suture.
Fimosi - Circoncisione - Prepuzioplastica - Sutura continua.

Introduction

The phimosis is an abnormal constrictive ring of the prepuce, at the reflection zone between internal and external preputial lamina, which does not allow the normal retraction of the foreskin. Therapeutic approaches are circumcision, preputial plasty, and topical steroids or nonsteroidal antiinflammatories (1). Topical antiin-

flammatory drugs may solve pseudophimosis or congenital phimosis in children. Circumcision is the oldest and the most common elective procedure. About 1 out of 6 boys and men in the world has been circumcised (2).

In recent years, the value of foreskin properties as well as aesthetic reasons determined to other operations preserving the foreskin, by using plastic surgery techniques to enlarge the preputial opening without complete removing tissue. An interesting prepuce plasty suggested by Homlund was a limited dorsal incision of the phimotic prepuce with transverse skin closure (3); although it is not without complications or re-operations (4-7). We report 5-years experience with a procedure that maintains the foreskin appearance intact.

"Sapienza" University of Rome, Rome, Italy
Department of Plastic Surgery

© Copyright 2013, CIC Edizioni Internazionali, Roma

Patients and methods

Fifty-two patients, eligible to undergo phimosis surgery, were recruited between 2006 and 2011. The youngest patient was 18 years old; the oldest was 81; the median age was 48 years. All patients underwent to prepuce-sparing plasty and simple running suture, under dorsal penile nerve block using carbocaine 5 cc plain at 10 and 2 o'clock at the base of the penis with a 27-Gauge needle.

Prepuce-sparing plasty

The incision lines are marked obliquely under phimotic ring, with the prepuce in tension using by two Gillies hooks or surgical pliers. The first incision is made on the external lamina of the prepuce, following the operative design (Fig. 1 A). It thus exposes the internal preputial lamina (Fig. 1 B). The second incision is performed on the internal lamina in an oblique opposite direction to the first one incision, in order to allow the total removal of the phimotic ring (Fig. 1 C) and to increase the circumference of the two laminae that are then realigned and sutured with 5/0 Monocryl by simple running sutures (Fig. 1 D).

Simple running suture

It is an uninterrupted series of simple interrupted sutures that avoids the knots. The suture starts by placing a simple interrupted stitch, which is tied but not cut. A series of simple sutures are placed in succession without tying or cutting the suture material after each pass. Sutures are evenly spaced, and tension is evenly distributed along the suture line. The line of stitches is completed by tying a knot after the last pass at the end of the suture line (Fig. 1 D).

Postoperative management

We discharged the patient with a moderate compressive bandage and oral antibiotic for three days. Follow-up was at 3, 7, 15 days, and 1, 3, 6 months. Evaluation of results was by pre and post-operative comparative photos. We verified the recurrence, the scarring, and the patient satisfaction by a Visual Analogue Scale (VAS) with a scoring system 0 to 10 (poor to excellent result).

Results

Surgery was performed with success in every patient, lasting 15 to 25 minutes. Thirty-nine patients were undergone also to frenuloplasty. Every patient was discharged after surgery.

At short-term follow-up, complete healing was in 48

cases. Four patients had a persistent edema; of these, 2 cases regressed with oral corticosteroid and 2 cases of diabetic patients regressed with a natural anti-edema plus vitamin E. There were neither cases of bleeding nor infection. Histology showed 16 cases of lichen sclerosus. In these cases, vitamin A ointment was recommended for 3 weeks.

At long-term follow-up, there was no pathological scarring. The scar showed a normal vascularity, normal pigmentation, good pliability, and a thin thickness. There were no phimosis recurrences.

VAS for patient satisfaction showed a score average of 8.54. All patients said they had restarting the normal sexual activity. In all cases, we observed a good aesthetic outcome and a natural appearance (Figs 2 A-B).

Discussion

The foreskin is a fold of skin that is assigned the task of protecting the glans (8). In order to maintain the prepuce in phimosis surgery, many authors suggested their technique of prepuceplasty (5). Currently, surgery of phimosis is conducted through two types of procedures: *a*) circumcision (complete postectomy), involving the total removal of the foreskin (9); it is classically considered the gold standard for phimosis, but it is less effective in terms of aesthetic result (10); *b*) prepuce plasty, according to two main methods: *i*) vertical incisions of the preputial ring, then sutured transversely; this technique is suitable for phimosis non-tight, and is more effective than the circumcision with regard to the postoperative course, especially bleeding and dysuria (10); *ii*) subtotal excision of the prepuce (incomplete postectomy); in this technique, the glans will be covered for 50% or more (11).

The value of foreskin properties as well as aesthetic reasons have led to a widening of the studies of the foreskin preserving. In 1973, Homlund opened this field with a dorsal incision of the phimotic prepuce and transverse skin closure with absorbable sutures (3). Subse-

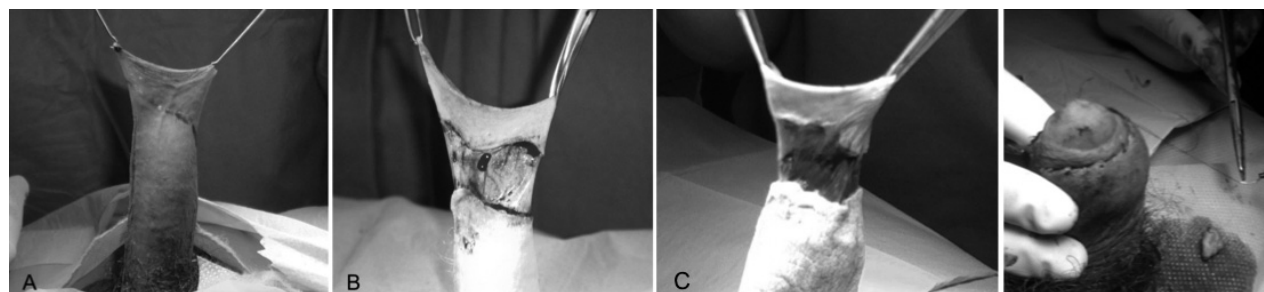


Fig. 1 - A-D - The first incision line is marked on the external lamina obliquely under phimotic ring, with the prepuce in tension (A). After incision of the external lamina, the internal preputial lamina is exposed (B). The second incision is marked on the internal lamina in an oblique opposite direction to the first one incision, in order to increase the diameter of the preputial laminae, with total removal of the phimotic ring (C). The two laminae are aligned and sutured by simple running sutures (D).

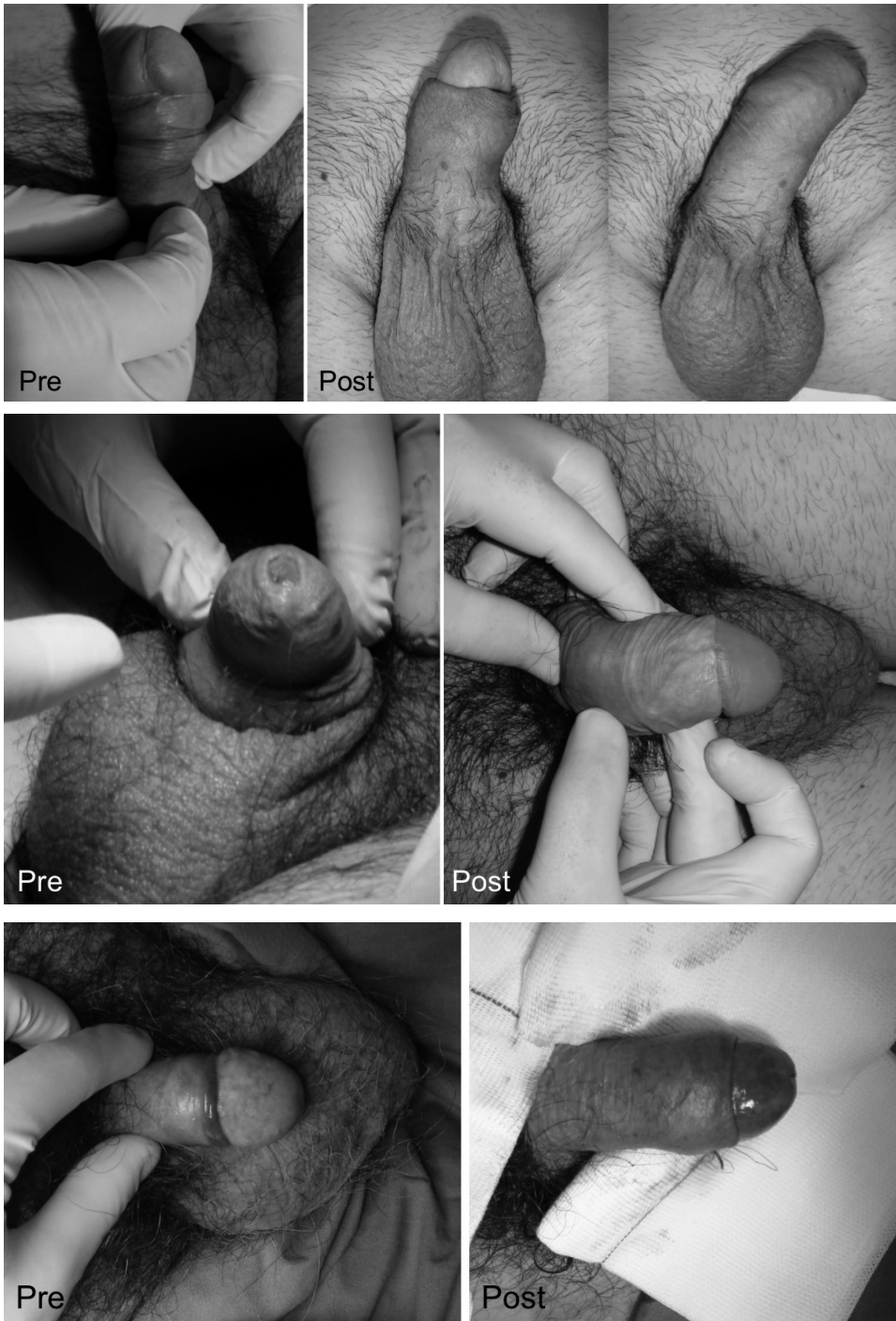

Fig. 2 A-B – Pre- (A) and post- (B) operative.

quently, the prepuce-plasty was reported as variation of Z-plasty, multiple Y-V-plasties, lateral preuceplasty, multiple internal foreskin lamina and triple incision plasty (12-16). We report an easy technique based on the incomplete postectomy with continuous sutures. Its rationale is based on the removal of the phimosis ring using oblique lines of incision, which increases the diameter

of the preputial laminae (Fig. 1 A-D). This will ensure the prevention of recurrence. We stretch the skin of the foreskin above the glans with two hooks, then we do a first oblique incision on the external lamina and a second oblique incision on the internal lamina, and remove the phimosis ring. The two laminae now have greater circumference and are sutured with monocryl by simple run-

ning sutures. So, the widening of the foreskin is permanent. The suture is faster, easier and without complications, with excellent cosmetic results.

The knotless also possesses significant advantages. The knots may induce greater tissue reaction, can cause decubitus or dehiscence especially on the mucosa, and the foreskin retraction is painless in the knotless. We use the Monocryl, although Vicryl is the synthetic polyester usually used. There are few *in vivo* studies evaluating the tissue reaction to suture materials (5). Both are absorbable: degrade with hydrolysis and cause minimal tissue reaction. We prefer Monocryl because of the greater breaking resistance and superior pliability, leading to ease in handling in the simple running suture. Moreover, the monofilament (Monocryl) versus multifilament (Vicryl) is a structure relatively more resistant to harboring microorganisms. Finally, the complete absorption is a little slower, significantly in some patients with risk factors for delay wound healing (diabetes, stress, systemic disease, and corticosteroid therapy).

Conclusion

The described procedure removes the phimosis maintaining the functional properties and natural morphology of the prepuce. Therefore, we believe that the use of prepuce-sparing plasty and simple running suture is a simple and effective method for the correction of acquired phimosis in adult patients.

The long-term success rate was high, and most patients were satisfied. Moreover, this technique can provide a suitable and reliable option for phimosis surgery when the patient wants to avoid the total postectomy/circumcision and maintain the physical foreskin appearance intact.

We believe that it represents a simple and reproducible technique for the management of the phimosis and it yields excellent functional and cosmetic results.

Competing interests

The authors declare that they have no conflict of interest.

References

1. Van Howe RS. Cost-effective treatment of phimosis. *Pediatrics* 1998;4:43.
2. Malone P, Steinbrecher H. Medical aspects of male circumcision. *BMJ* 2007;335:1206.
3. Holmlund DE. Dorsal incision of the prepuce and skin closure with Dexon in patients with phimosis. *Scand J Nephrol* 1973;7:97-9.
4. Barber NJ, Chappell B, Carter PG. Is prepuceplasty effective and acceptable? *J R Soc Med* 2003;96:452-3.
5. Christianakis E. Sutureless prepuceplasty with wound healing by second intention: an alternative surgical approach in children's phimosis treatment. *BMC Urol* 2008;8:6.
6. Fleet MS, Venyo AKG, Rangecroft L. Dorsal relieving incision for non retractile foreskin. *J R Coll Edinb* 1995;40:243-5.
7. Saxena AK, Schaarschmidt K, Reich A, Willital GA. Non-retractile foreskin: a single center 13-year experience. *Int Surg* 2000;85:180-3.
8. Williams. *Gray's Anatomy*. 37 ed. Churchill Livingstone, New York 1989:1432.
9. Bertone FF. *Pediatric surgery*. Welch KJ et al. Year Book Medical Publishers, Inc. Chicago 1986;133:1314.
10. Cuckow PM, Rix G, Mouriquand P. Preputial plasty: a good alternative to circumcision. *J Pediatr Surg* 1994;29:561-3.
11. Hofmann-von Kap-herr S. Circumcision in Germany: editorial comments. *Pediatr Surg Int* 1999;4:227-8.
12. Emmett AJ. Z-plasty reconstruction for preputial stenosis – a surgical alternative to circumcision. *Aust Pediatr J* 1982;18:219-20.
13. Hoffman S, Metz P, Ebbehøj J. A new operation for phimosis: prepuce saving technique with multiple Y-V plasties. *Br J Urol* 1984;56:319-21.
14. Lane TM, South LM. Lateral preputioplasty for phimosis. *J R Coll Surg Edinb* 1999;44:310-2.
15. Houdelette P, Peyrottes A, Wodey J. Procédé plastique conservateur par plastic en Z asymétrique. *J Urol (Paris)* 1991;97:148-9.
16. Wahlin N. Triple incision plasty. A convenient procedure for preputial relief. *Scand J Urol Nephrol* 1992;26:107-10.