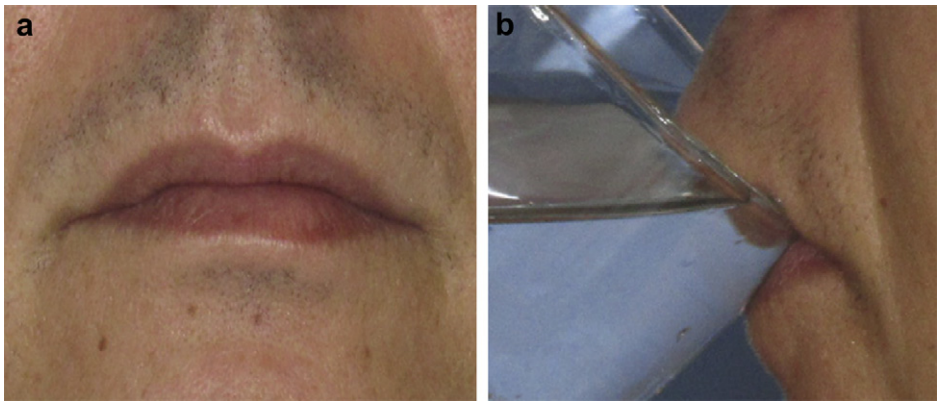

Figure 2 Male a) Lip wrinkles at rest. b) Dynamic lip wrinkles drinking from a glass. Men tend to keep their upper lip taught whilst drinking.

Drinking is one of the most common human activities and our findings suggest there are gender specific drinking patterns related to development of perioral wrinkles. Women 'pucker' and men are 'tight lipped'. Twenty-one (70%) of 30 women, of whom 13 (43.3%) had a WS >30 but <90 and 9 (30%) with a 'severe' score, typically made their lips pucker whilst drinking from a glass, causing orbicularis oris muscle to contract in a 'J' shaped, sphincteric pattern, promoting wrinkle formation. In comparison, twenty-four (80%) of 30 men, of whom 12 (40%) with 'mild' score and 16 (53.3%) with 'moderate' score, tended to keep their upper lip taught whilst drinking.

Each time the puckering action of orbicularis oris is used, a groove forms beneath the surface of the skin and, as skin ages, it loses its flexibility and is no longer able to spring back in place and collagen fractures appear. These grooves become permanent features. In this context, it is interesting also to note that the orbicularis oris muscle is anchored 1.5 times closer to the dermis in women than in men and the fibrous connections between the muscle and the dermis can cause an inward traction, thereby creating deeper wrinkles.[6] The structural gender differences could play an important role in perioral wrinkle formation and our observation that women tend to use a different pattern of orbicularis oris action in drinking, one of the most frequent daily activities, is a likely explanation of why perioral wrinkles are more common and more severe in women and contribute to improve our understanding of wrinkle formation.

Conflict of interest statement

None declared.

References

1. Rexbye H, Petersen I, Johansens M, et al. Influence of environmental factors on facial ageing. *Age Ageing* 2006;**35**:110—5.
2. Sveikata K, Balciuniene I, Tutkuviene J. Factors influencing face aging. Literature review. *Stomatologija* 2011;**13**(4):113—6.
3. Raitio A, Kontinen J, Rasi M, Bloigu R, et al. Comparison of clinical and computerized image analyses in the assessment of skin ageing in smokers and non-smokers. *Acta Derm Venereol* 2004;**84**:422—7.
4. Castelo-Branco C, Pons F, Gratacos E, et al. Relationship between skin collagen and bone changes during aging. *Maturitas* 1994;**18**:199—206.
5. Caisey L, Gubanova E, Camus C, et al. Influence of age and hormone replacement therapy on the functional properties of the lips. *Skin Res Technol* 2008;**14**:220—5.
6. Paes EC, Teepen HJLJM, Koop WA, Kon M. Perioral wrinkles: histologic differences between men and women. *Aesthet Surg J* 2009;**29**(6):467—72.

Rosaria Laporta
Sant'Andrea Hospital, School of Medicine and Psychology, "Sapienza" University of Rome, Via di Grottarossa 1035-1039, 00189 Rome, Italy

Nigel Mercer
Bristol Plastic Surgery, 58 Queen Square, Bristol BS1 4LF, United Kingdom
E-mail address: nm@bristolplasticsurgery.com

http://dx.doi.org/10.1016/j.bjps.2012.11.002

Reconstruction of posterior auricular ear surface defects: "Ear Keystone graft"

Dear Sir,

Malignant cutaneous tumors are common on the external ear[1] and reconstruction of posterior auricular surface's defects after surgical removal of cancer can be performed using different strategies. These techniques can be not easy or not really quick to perform, therefore we believe that it can be useful to propose another strategy to evaluate between the different reconstructive options in this anatomical region.

The Keystone Design Perforator Island Flap (KDPIF), a curvilinear shaped trapezoidal design flap described by Felix C Behan in 2003,[2] is a solution to reconstruct soft tissue defects in head and neck, trunk, and extremities. Based on fasciocutaneous perforators, this flap offers both the robust vascularity of perforator flaps and the relative ease and speed of local tissue rearrangement.

In this regard we present our experience with the use of the KDPIF for the posterior surface of the auricle's reconstruction after removal of a skin epithelioma. This application of KDPIF has never been described in literature and it is a special feature due to the lack of perforating vessels that supply blood to the flap in this anatomical region.

In our case the lesion was removed using an excision of elliptical shape located on the side face of the helix. The reconstruction of the excision area was performed using the Keystone Flap with a mediolateral translation. The flap was designed according to the instructions provided by Behan[2] (Figure 1) but we didn't undermine the flap using the so-called "blunt dissection[2]", and we took care to ensure that the incision was full thickness up to the ear perichondrium (Figure 2).

The postoperative period was uneventful and the esthetic result was excellent (Figure 3).

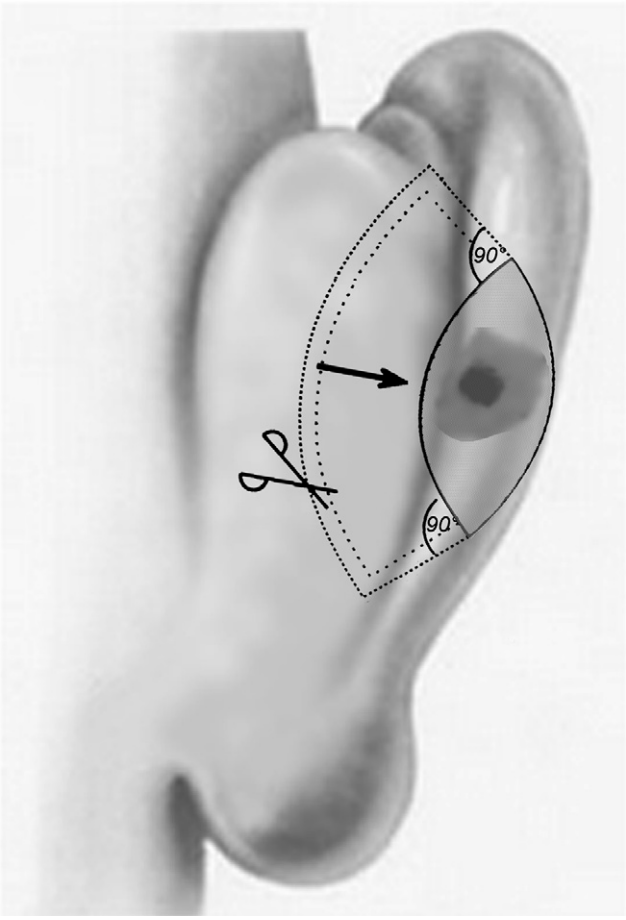

Figure 1 Schematic image of our modified keystone.

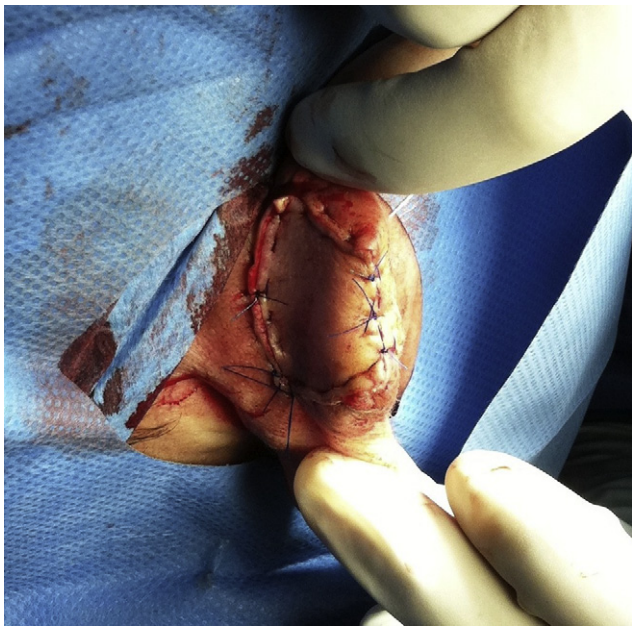

Figure 2 Intraoperative view.

We designed Keystone flap in a particular zone, the posterior surface of right auricula, and we used this flap in order to exploit its unique capabilities of skin tension lines distribution in an area with low skin laxity as the ear. The posterior surface of auricle's skin is thin, densely attached to the perichondrium and it is devoid of subcutaneous tissue. The fascial layer between the skin and perichondrium contains a subdermal plexus of vessels and the literature[3] does not describe vessels piercing the cartilage skeleton from the lateral face of the pinna to the posterior one. Given its special vascular characteristics we called this flap

Figure 3 Postoperative view at 4 weeks.

"Keystone-graft" because it could be a way to use the posterior ear skin as a full thickness graft and designing the harvest in a way that direct closure is possible through keystone design.

Since the creation of the flap, in fact, the perimetral incisions were performed up to the perichondrium and the vessels that normally supply the skin perforators (the posterior auricular artery and superficial temporal arteries[4]) were interrupted. The resulting lack of blood supply from the perforating arteries would cause the ischemia of the flap, so its survival and nourishment must depend on other mechanisms.

Evaluating the characteristics of our Keystone it reveals some features that could lead to a possible explanation. First of all the skin of the helix is very thin and strongly adherent to the underlying perichondrium.[3] Moreover cartilage tissue is poorly vascularized, perichondrium instead presents vessels that nourish the cartilage itself not directly but through the diffusion of molecules. Finally a skin graft can survive without a vascular pedicle thanks to three main factors: the direct connection of the graft vessels with the host ones, the vessel proliferation of the receiver vessels in the endothelial channels of the graft ones and penetration of host blood vessels in the vessels of the receiver with the formation of new endothelial channels.[5]

Seeing that our flap could not feed through the perforating vessels, our theory is that the flap has initially survived as a graft and then developed its own blood supply. In this way, it is possible to exploit the characteristics of the distribution of skin tension lines typical of the Keystone flap, but not its vascular supply. Conversely it could be remained in life due to the reduced thickness of the ear skin which allowed the exchange of molecules from the blood by diffusion.

We think that the use of "Keystone graft" in the posterior auricular ear surface has, therefore, some advantages such as a considerable possibility of translational movement of the flap with a capacity of closure of large losses of substance, the exploitation of the ability to break and re-distribute the skin tension lines allowing a better distribution of the forces acting on the flap and a better esthetic result, because there is no damage of the donor site and the color and quality of skin used by the flap are identical to the skin in the area of the loss of substance. Moreover the "Ear Keystone-graft" grants a better esthetic result because the scars of the flap perimeter appear flat and not dyschromic or flared and it is rapid and easy to perform.

Conflict of interest statement

None of the authors received any funds or has any financial interests to disclose.

References

1. Pless J. Carcinoma of the external ear. *Scand J Plast Reconstr Surg* 1976;**10**:147–51.
2. Behan FC. The keystone design perforator island flap in reconstructive surgery. *ANZ J Surg* 2003;**73**:112–20.
3. Testut L, Latarjet A. *Traitè d'anatomie humaine*. Paris: G.Doin & C.ie; 1971. p. 741–742.
4. Pinar YA, Ikiz ZA, Bilge O. Arterial anatomy of the auricle: its importance for reconstructive surgery. *Surg Radiol Anat* 2003; **25**:175–9.
5. Converse JM, McCarthy JG, Littler JW. *Reconstructive plastic surgery, principles and procedures in correction, reconstruction and transplantation, volume one, general principles*. 2nd ed. Philadelphia PA: Saunders Company; 1977. p. 163–171.

Federico Corrias
Michele Maruccia
Cristiano Monarca
Giuseppe Sanese
Nicolò Scuderi
Department of Plastic and Reconstructive Surgery, Sapienza University of Rome, Viale del Policlinico 155, 00161 Rome, Italy
E-mail address: marucciam@gmail.com

http://dx.doi.org/10.1016/j.bjps.2012.10.009

Microscope-integrated indocyanine green videoangiography for deep inferior epigastric perforator flap

Dear Sir,

Autologous breast reconstruction with Deep Inferior Epigastric Perforator (DIEP) flap has become a popular technique, due to a natural cosmetic shape and a low abdominal donor-site morbidity. A preoperative computed tomographic analysis of the Deep Inferior Epigastric Artey (DIEA) perforators is usually made to select the valuable perforators, according to their course and caliber.[1] However, the occurrence of fat necrosis or a partial flap loss is not rare in DIEP flap, despite a preoperative planning and a good operative technique.[2]

To avoid these issues, a very precise delineation of the DIEP survival skin paddle can be performed by determining directly the perforasomes of the DIEA.[3] For this purpose, we developed a procedure using an intraoperative fluorescent videoangiography, immediately after the dissection of the musculocutaneous perforators and the source artery. The DIEA is ligated downstream from the dominant perforator and transected at its origin, before the procedure. Then, an intravascular injection of 5 ml of indocyanine green (Infracyanine 25 mg, Laboratoire Serb, Paris, France) is performed into the DIEA. The dilution used is 25 mg indocyanine green/20 ml NaCl. The indocynanine green reaches in a few seconds the subdermal and dermal plexus of the abdominal flap. Immediately after the injection, a near infrared digital video camera (FL800 NIR Sony XC-EI 50 Camera, Sony Corp., Tokyo, Japan) integrated in a surgical microscope M525